

Retinal Endoscopy, Illumination, and Photocoagulation

The endoscope allows visualization and treatment of structures that would otherwise remain hidden.

**BY JORGE G. ARROYO, MD, MPH; TAIGA KINOSHITA, MD;
AND KYLE D. KOVACS**



Retina Pearls is a column that appears regularly in Retina Today. The purpose of the column is to provide a forum for retinal specialists to share informative and exciting tips or pearls with regard to specific vitreoretinal surgical techniques, diagnostics, or therapeutics. This installment of Retina Pearls addresses retinal endoscopy,



illumination, and photocoagulation. Jorge G. Arroyo, MD, MPH, Taiga Kinoshita, MD, and Kyle D. Kovacs provide pearls on using an illuminated endoscope to perform procedures in the peripheral retina.

We extend an invitation to readers to submit surgical pearls for publication in Retina Today. Please send submissions for consideration to Dean Elliott (deliott@doheny.org) or Ingrid U. Scott, MD, MPH (iscott@psu.edu). We're looking forward to hearing from you.

-Dean Elliott, MD; and Ingrid U. Scott, MD, MPH

In the years before the invention of the ophthalmoscope, the back of the eye in the living human was essentially a black box, an impenetrable void. In 1851, when Helmholtz invented the ophthalmoscope, the posterior segment—this miniature world that had been hidden—suddenly appeared to our eyes. It is astounding how quickly ophthalmologists recognized the potential of the Helmholtz device and put it to use. Within 2 years, retinal tear had been described. The following year, von Graefe described retinal detachment. This glimpse back at history shows dramatically how, once one is able to see something new, many discoveries and much progress can follow.

In a similar fashion, one part of the eye has remained

hidden or difficult to see until fairly recently: the area immediately behind the iris, including the ciliary body, the ciliary processes, and the far anterior reaches of the peripheral retina and vitreous. The ciliary processes, for instance, are hidden from our view except in rare cases of aniridia, coloboma, or trauma. Even with scleral depression and special contact lenses, we can barely see to examine them in normal eyes.

These retroiridal areas of the eye are hidden from everyday view in both the clinic and the operating room. The endoscope opens up this region of the globe for investigation, diagnosis, and treatment. The beauty of the endoscopy system we use (Uram E2, Endo Optiks, Little Silver, NJ) is that it provides endoscopy, endoillumination,

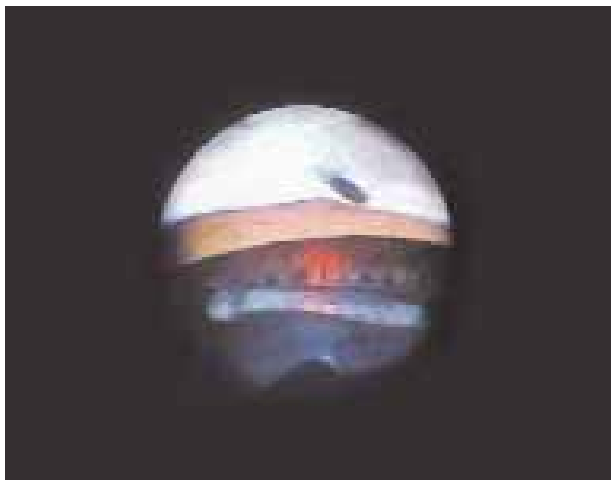


Figure 1. Endoscopic view of a well-placed IOL haptic.

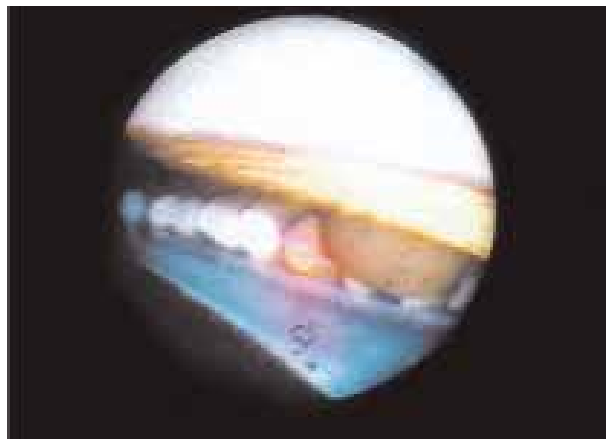


Figure 2. Endoscopic view of a pigmented iris cyst located near the ciliary processes.

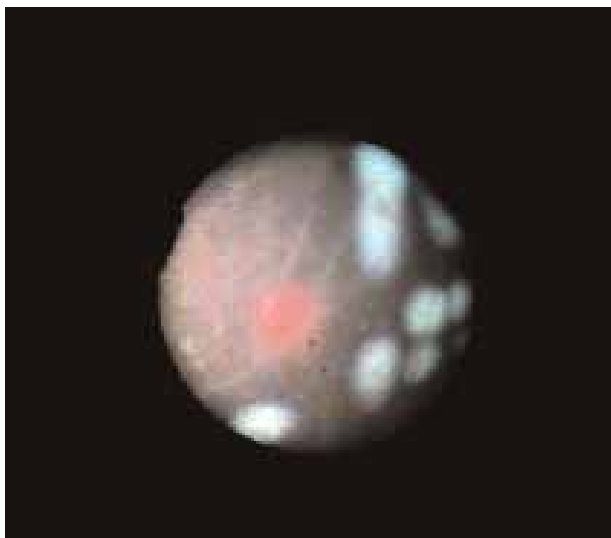


Figure 3. Endoscopic view shows the red aiming beam, the sclerotic vessels suggesting a very ischemic retina, and the laser spots already applied.

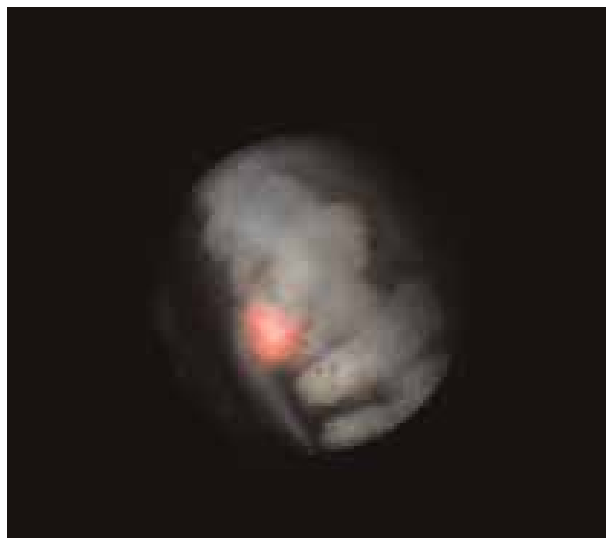

Figure 4. Endoscopic view of posterior endoscopic cyclophotocoagulation, showing the aiming beam on the ciliary processes.

nation, and endophotocoagulation at the same time, all through a 20-gauge sclerotomy.

Endoscopy has been available to ophthalmologists since the early 1990s. I know this because I did my residency at University of California, San Francisco with glaucoma specialist Jorge A. Alvarado from 1992 through 1995. At that time, he was compiling the cases reported in his paper on endoscopic photocoagulation of the ciliary body for treatment of refractory glaucomas.¹

Still, even 15 years later, endoscopic technology has not been as widely accepted as some might have thought. Yet it can be an invaluable tool for ophthalmologists. This paper outlines some of what we have

learned about the advantages and the limitations of endoscopic technology for posterior segment surgery.

BEHIND THE IRIS

In ophthalmology, if we cannot see the problem we cannot fix the problem. The endoscope affords us another set of eyes, allowing us to treat patients that we could not have treated otherwise.

There are rare cases where the pathology is in this dark space, this hidden area behind the iris. For example, uveitis-hyphema-glaucoma (UGH) syndrome is not common, but it often requires surgical intervention. In a number of these cases over the years, the endoscope has been helpful. It allows us to visualize the IOL haptic

Posterior endoscopic laser is
invaluable in patients with rubeosis
iridis and neovascular glaucoma.

behind the iris (Figure 1), so we can see whether it is eroding into the ciliary processes or ciliary body, causing recurrent bleeding and inflammation. Endoscopy allows us to identify the problem so that we can fix it.

As another example, the endoscope can also help to locate intraocular foreign bodies or structural abnormalities behind the iris, such as iris cysts (Figure 2).

Again, in patients with idiopathic recurrent vitreous hemorrhage, the source of abnormal blood vessels is sometimes in the vitreous base or the far retinal periphery and cannot be seen with conventional ways of looking at the retina. Using the endoscope we are able to find the source of bleeding and coagulate that area.

Most retinal tears can be seen with scleral depression, but if the tear is in the far periphery and the view is difficult, even with scleral depression one might not be able to identify abnormalities. In these cases the endoscope can be employed to identify and treat the retinal breaks.

VITREOUS SURGERY, LASER

In patients with opaque or very hazy media, such as severe corneal edema, the view of the retina can be difficult or nonexistent. In these patients, endoscopy makes possible surgery that would otherwise be impossible. We can remove vitreous without seeing it through the microscope, using only the endoscope.

Admittedly, performing a vitrectomy with the endoscope is definitely more difficult than performing one using the microscope. The obvious reason is that the microscope provides binocularity and depth perception, or more precisely stereopsis. Using the endoscope we lose stereopsis, and the point of view or perspective changes every time we move the endoscope. There is definitely a learning curve, and it takes time before one gets comfortable with the lack of stereopsis and the shifting perspective.

Posterior endoscopic laser is invaluable in patients with rubeosis iridis and neovascular glaucoma. In these patients, in whom often the cornea is edematous and the view is poor, with endoscopy we can do extensive and thorough peripheral laser treatment to the retina and treat the ciliary processes with endoscopic cyclophotocoagulation (ECP) as well in the same session.

The laser treatment is relatively quick and easy.

We recently reviewed our experience with this procedure in patients with neovascular glaucoma at Beth Israel Deaconess Medical Center. We compared results in eight eyes that underwent endoscopic laser and ECP with results in six eyes that underwent pars plana vitrectomy and endolaser only with no ECP. Follow-up was at least 1 year. At final follow-up, mean intraocular pressure was approximately 10 mm Hg lower in patients who received the ECP treatment (13.3 mm Hg) than in patients who did not receive ECP (23.3 mm Hg).

CONCLUSIONS

Combined endoscopy, illumination, and photocoagulation offers a number of advantages to the retinal surgeon. It allows excellent visualization of the region behind the iris, as well as the vitreous in eyes with opaque media. It facilitates treatment of the peripheral retina. And it seems to be an effective treatment in patients with neovascular glaucoma, although further study is warranted. Looking toward the future, no one can say what further applications will be found for endoscopy, but it is a useful tool with great potential for innovative uses.

Jorge G. Arroyo, MD, MPH, is Director of the Retina Service at Beth Israel Deaconess Medical Center (BIDMC) of Harvard Medical School, Boston. The authors report no financial interests. Dr. Arroyo may be reached at +1 617 667 3391; or via e-mail at jarroyo@bidmc.harvard.edu.



Taiga Kinoshita, MD, is a Vitreoretinal Research Fellow on the Retina Service at BIDMC. He may be reached at +1 617 667 3391.

Kyle D. Kovacs, BA, is a Clinical Research Assistant on the Retina Service at BIDMC. He may be reached at +1 617 667 5803.

Dean Elliott, MD, is a Professor of Ophthalmology and Director of Clinical Affairs, Doheny Eye Institute, Keck School of Medicine at USC and is a member of the Retina Today Editorial Board. He may be reached by phone: +1 323 442 6582; fax: +1 323 442 6766; or via e-mail: deliott@doheny.org.

Ingrid U. Scott, MD, MPH, is a Professor of Ophthalmology and Public Health Sciences, Penn State College of Medicine, Department of Ophthalmology, and is a member of the Retina Today Editorial Board. She may be reached by phone: +1 717 531 4662; fax: +1 717 531 5475; or via e-mail: iscott@psu.edu.

1. Chen J, Cohn RA, Lin SC, Cortes AE, Alvarado JA. Endoscopic photocoagulation of the ciliary body for treatment of refractory glaucomas. *Am J Ophthalmol*. 1997;124(6):787-796.